



Amoebic Liver Abscess with Empyema

Redo Kurniawan¹, Raveinal², Arnelis³

¹ Departemen Ilmu Penyakit Dalam, Fakultas Kedokteran Universitas Andalas, Padang 25163, Indonesia

² Departemen Ilmu Penyakit Dalam Divisi Alergi Imunologi, Fakultas Kedokteran Universitas Andalas, Padang 25163, Indonesia

³ Departemen Ilmu Penyakit Dalam Divisi Gastroenterologi dan Hepatologi, Fakultas Kedokteran Universitas Andalas, Padang 25163, Indonesia

ABSTRACT

Abstrak

Pendahuluan: Abses hepar merupakan peradangan supuratif pada parenkim hepar yang dapat disebabkan oleh bakteri, jamur atau mikroorganisme seperti parasit. Kejadian amubiasis terjadi pada 10% dari populasi dunia dan paling umum terjadi pada daerah tropis dan subtropis. Penyakit ini sering di derita pada usia muda dan berisiko 10 kali pada pria dibandingkan wanita. Penatalaksanaan invasif amoeba sebaiknya dilakukan pemberian amebisid jaringan, seperti metronidazol dan tinidazole.

Laporan Kasus: Telah dirawat seorang pasien laki-laki, usia 42 tahun di bagian Penyakit Dalam RSUP Dr. M. Djamil Padang dengan abses hepar amoeba dengan empiema ec abses hepar amoeba. Keluhan utama pada pasien berupa sesak napas dan nyeri perut kanan atas sejak 1 minggu yang lalu. Pemeriksaan fisik hemitoraks kanan pasien didapatkan suara napas menghilang setinggi RIC II, dan pemeriksaan fisik abdomen terdapat nyeri tekan hipokondrium kanan dan hepatomegali. Pemeriksaan laboratorium terdapat leukositosis 15.970/mm³, dan anti amoeba positif 92,4. Rontgen toraks pasien didapatkan kesan efusi pleura masif dekstra dan USG abdomen terdapat lesi desak ruang ukuran 11,57cm x 9,65cm dengan kesan abses hepar dd/ hepatoma. Pada pasien diberikan terapi metronidazole injeksi 3x750mg selama 10 hari dan selama rawatan pasien menunjukkan perbaikan secara klinis.

Kesimpulan: Kejadian abses hepar pada kasus ini merupakan suatu proses peradangan yang disebabkan oleh amoeba. Terjadinya empiema pada kasus ini merupakan komplikasi hepatopulmoner secara langsung dari abses hepar.

Kata kunci: Abses Hepar, Abses Hepar Amoeba, Empiema

Abstract

Introduction: Liver abscess is a suppurative inflammation of the liver parenchym which can be caused by bacteria, fungi or microorganisms such as parasite. Amebiasis occurs in 10% of the world's population and is most common in tropical and subtropical areas. This disease is often suffered at a young age

10 times more risking in men than women. Invasive amoeba management should include tissue amebicides, such as metronidazole and tinidazole.

Case Report: A male patient, 42 years old, has been treated in the Internal Medicine Department of Dr. M. Djamil Padang with amoebic hepatic abscess with empyema ec amoebic hepatic abscess. The patient's main complaints were shortness of breath and upper right abdominal pain since 1 week ago. Physical examination of the right hemithorax found disappearance of breath sounds as high as RIC II, and physical examination of the abdomen found right hypochondrial tenderness and hepatomegaly. Laboratory examination found leukocytosis 15,970/mm³, and positive anti-amoeba 92.4. The expertise of patient's chest X-ray showed a massive right pleural effusion and abdominal ultrasound found an space occupying lesion measuring 11.57cm x 9.65cm with the appearance of a hepatic abscess dd/ hepatoma. The patient was given metronidazole injection 3x750 mg for 10 days and during treatment the patient showed clinical improvement.

Conclusion: Liver abscess in this case is an inflammatory process caused by amoeba. The occurrence of empyema in this case is a direct hepatopulmonary complication of liver abscess.

Keyword: Liver abscess, Amoebic liver abscess, Empyema

Apa yang sudah diketahui tentang topik ini?

Diagnosis dan penanganan abses hepar amoeba dengan empiema.

Apa yang ditambahkan pada studi ini?

Kasus Abses Hepar Amoeba dengan Empiema.

CORRESPONDING AUTHOR

Phone: +6282285120139

E-mail: redokurniawan0123@gmail.com

ARTICLE INFORMATIONReceived: May 14th, 2023Revised: June 6th, 2023Available online: June 16th, 2023**Introduction**

Amoebic liver abscess is the most common extraintestinal manifestation of the *Entamoeba histolytica* protozoan infection which occurs due to accumulation of purulent necro-inflammatory debris in the liver parenchyma. Amoebiasis is the parasitic infection caused by the protozoa *Entamoeba histolytica*, with fecal-oral transmission. The infection could cause varying manifestations, ranging from asymptomatic to several complications associated with liver abscess.^{1,2}

Colon amoebiasis, if untreated, could expand past the intestine causing extraintestinal amoebiasis which occurs hematogenously and percontinitatum. Hematogenic spread occurs if the amoeba has entered the submucosa and then into the blood capillaries. Percontinitatum spread occurs if the liver abscess is ruptured and the amoeba exits past the diaphragm, entering the pleural cavity and the lungs thus causing lung abscess or empyema.^{2,5,6}

Case Illustration

A male patient, aged 42 years old, had been treated in the Internal Medicine Department of RSUP Dr. M. Djamil Padang since March 10th, 2023 at 00:22 WIB with increasing shortness of breath since 1 week prior to admission. Shortness of breath was not affected by activity, weather, food, and the patient felt relieved when lying facing the right side. The abdomen was felt to gradually enlarge within the last 6 months and within those 6 months there was a weight loss of 20 kilograms. Coughing since 2 weeks prior, no phlegm. Appetite loss since 1 month prior. Fatigue since 2 weeks prior. Fluctuating fever since 1 week prior, minimally elevated temperature and without chills. Pain in the upper right abdominal region felt as a stabbing sensation since 1 week prior, felt continuously and did not radiate. The pain increased while coughing, taking deep breaths, and lying facing the right side, was not relieved by positional changes. The patient

enjoyed consuming undercooked food. The patient lived in a permanent residence with adequate lighting and ventilation as well as good hygiene. Washing and other hygienic needs were done in a private latrine within the house. Daily source of water was from water wells. The patient had a history of smoking with an average of 1 cigarette pack consumed daily, as well as a history of alcohol consumption. The patient was referred from RSUD Arosuka, Solok Regency, previously treated for 1 week, during which the patient had undergone pleural tapping and 600 cc of blackish red fluid was collected with a cytological result of "acute exacerbated chronic inflammation". The patient had undergone abdominal ultrasound with results suggestive of a hepatoma. The patient was then referred to RSUP M Djamil for further examinations.

From general physical examination, the patient seemed to be moderately ill, blood pressure 100/70mmHg, pulse 96x/minute, respiratory rate 30x/minute, temperature 38.50C, oxygen saturation 98% with NRM 15 liters per minute and anemic conjunctiva. Inspection of the chest wall is asymmetrical and movement of the right chest wall is left behind. Palpation of the right chest wall is decreased compared to the left, and percussion of the right chest wall is duller than the left chest wall. Examination of right hemithorax auscultation: respiratory sounds inaudible from as high as ICS II, crackles (+/+), wheezing (-/-). On inspection the abdomen was seen to be distended, the liver palpated 3 fingers below the costal arch and 3 fingers below the xiphoid process, with sharp edges, hard consistency, flat surface, and tenderness on the right hypochondrium.

Laboratory examination results obtained Hb 8.9 gr/dl, hematocrit 28%, leukocytes 15,970/mm³, platelets 355,000/mm³, SGOT 19, SGPT 19, direct bilirubin 0.4 mg/dl, indirect bilirubin 0.2 mg/dl, albumin 2.1 g/dl and globulin 3.4 g/dl. Results of routine urinalysis and fecal analysis were within the normal range. Result of anti-amoeba test was positive 92.4. Pleural fluid

analysis suggested an exudate. The patient's sputum culture and pleural fluid culture results were negative.

Chest x-ray was suggestive of a massive right pleural effusion with bronchopneumonia (Figure 1). Abdominal ultrasound (Figure 2) showed a 11.57 cm x 9.65 cm space occupying lesion (SOL) suggestive of liver abscess with a differential diagnosis of a hepatoma. Figure 3 presented the results of chest ultrasound was suggestive of right pleural effusion. The patient was then diagnosed with amoebic liver abscess and empyema et causa liver abscess.

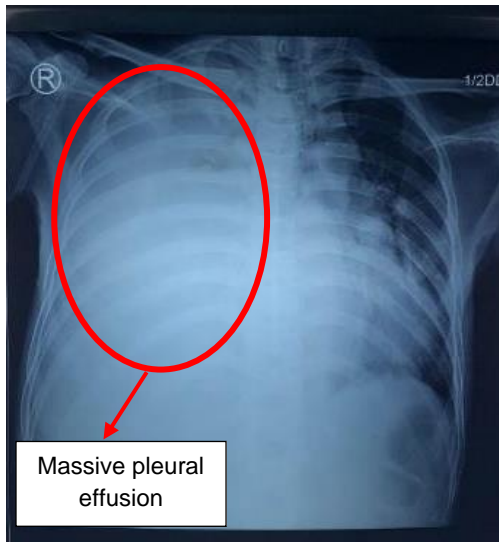


Figure 1. Chest x-ray

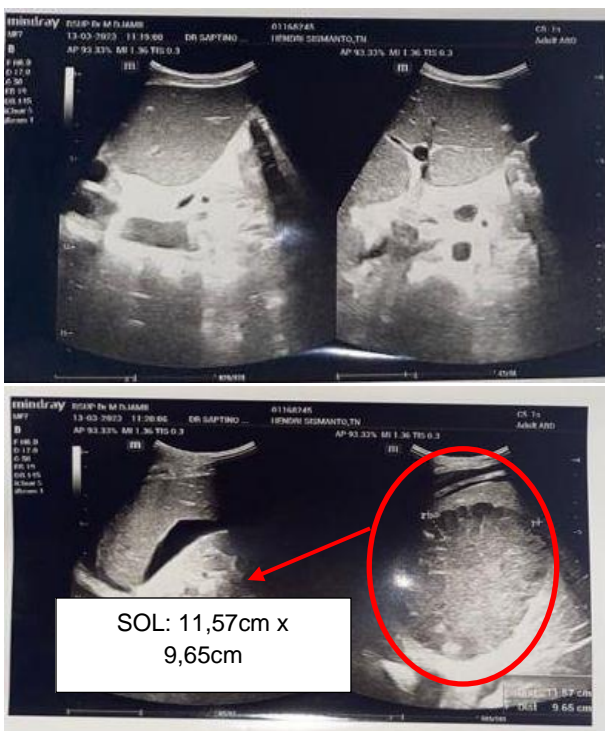

Figure 2. Abdominal ultrasound

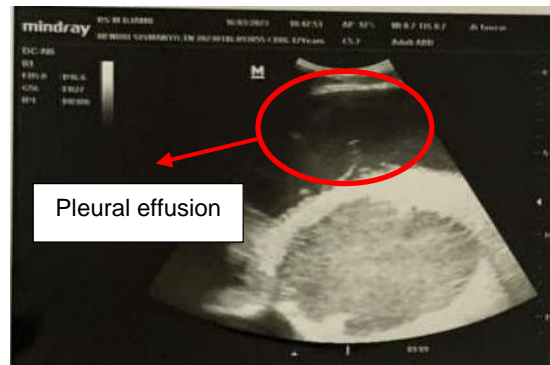


Figure 3. Chest ultrasound

A thoracentesis was performed on the patient and 1.5 liters of brownish liquid was evacuated. The patient received an antibiotics regimen of intravenous 750 mg Metronidazole three times a day for 10 days and intravenous 1 gram Ceftriaxone two times a day. During treatment, the patient also received 1 unit of PRC transfusion with post transfusion Hb level of 10.7 g/dl. The patient also received symptomatic medications such as oral 1000 mg Paracetamol three times a day, 100 cc transfusion of 20% albumin, slow release potassium three times a day, among others.

After 10 days of treatment, the patient's condition increasingly showed improvement, with decreased shortness of breath and right upper abdominal pain. The patient was then discharged on March 20, 2023.

Discussion

A male patient, aged 42 years old, had been treated in the Internal Medicine Department of RSUP Dr. M. Djamil Padang since March 10th, 2023 at 00:22 WIB with amoebic focal liver abscess and empyema et causa amoebic liver abscess.

Diagnosis of amoebic liver abscess was made through history taking, as the patient came with a complaint of right upper abdominal pain which increased since 1 week prior to admission. The pain was felt constantly, did not radiate, and felt like a stabbing sensation. The pain was aggravated while coughing, taking deep breaths, and lying facing the right side, and was not relieved by positional changes. Fever since 1 week prior to admission with minimally elevated temperature, with no excessive sweating nor chills. The patient also complained of fatigue and weight loss + 20 kg within the past 6 months. Through history taking,

the patient fits the clinical manifestations of amoebic liver abscess according to Nusi IA., 2014 which stated that 75-90% patients experienced right upper abdominal pain. Spontaneous right upper abdominal pain accompanied by a forward hunched gait are typical symptoms that were commonly found. The pain is typically intense and constant, radiates to the scapular and right shoulder area, aggravated by deep breathing or coughing, or while the patient lies facing the right side. Abdominal pain is occasionally accompanied by nausea and vomiting, appetite loss, weight loss, fatigue, and liver enlargement. Fever is commonly found in patients of liver abscess with a variety of fever pattern.

The patient complained of shortness of breath which increased within 1 week prior to admission, and the patient felt comfortable while facing to the right side. In patients with liver abscess, inflammatory lesion could expand to the pleural cavity, thus causing empyema or even lung abscess. One of the causes of expansion to the pleural cavity is a hepato-pleural fistula.

Regarding history of patient's habits, it was known that the patient enjoyed consuming uncooked food. Patient was of lower-middle socioeconomic status, and had a history of alcohol consumption + 5 years. According to Khim G, et al., 2019, major risk factors include poor sanitation, contaminated drinking water. According to Wuerz T, 2012, risk factors of amoebiasis include alcohol consumption, poor sanitation, immunocompromised conditions, and lower socioeconomic status.^{6,15}

From the patient's abdominal physical examination, it was supple on palpation, the liver was palpated 3 fingers below the costal arch, with sharp edges, hard consistency, flat surface, unpalpable spleen, and a tenderness on right hypochondrium region. Such data were compatible with the physical examinations of a liver abscess according to Dutta A, et al, 2012, which stated that the cardinal signs of amoebic liver abscess were hepatomegaly accompanied by pain.^{13,14}

Laboratory examination of the patient showed leukocytes 15,970/mm³, segment neutrophils 80%, positive anti-amoeba of 92.4 units. According to Khim G, et al, 2019, clinical presentations between amoebic and pyogenic

liver abscess could not be differentiated. Patients often present with fever and right upper abdominal pain. Laboratory examinations showed leukocytosis (mainly neutrophils), elevated inflammatory markers (such as C reactive protein), elevated alkaline phosphatase and abnormal liver function. In amoebiasis, a positive amoeba serology is obtained (70-95%). According to Nusi IA, 2015, in pyogenic liver abscess, laboratory examinations would show leukocytosis, anemia, elevated liver enzymes, elevated bilirubin level, hypoalbuminemia, and a positive blood culture (50-60%).^{14,15}

The patient's abdominal ultrasound result was suggestive of liver abscess. Abdominal ultrasound is the first choice of initial test, because it is non-invasive and has high sensitivity (80-90%) to detect hypoechoic lesions. It is typical of amoebic liver abscess to be solitary (80%), usually right lobe, rounded or oval, adjacent to the liver capsule. Meanwhile, in pyogenic liver abscess, the lesion is typically multifocal with irregular edges. It may also indicate an association with a right pleural effusion or the presence of a rupture.^{13,14}

For therapy, the patient was given intravenous 750 mg Metronidazole three times a day for 10 days, according to Loscalzo J., 2022 which stated administration of 750 mg Metronidazole three times a day for 10 days. According to Sharma A. 2021, management of liver abscess could be accomplished by combination strategy between medications and effective drainage to reduce abdominal pain and local tenderness, but not for resolution of fever, abscess convalescence, and duration of hospital stay, with limited benefits for abscesses larger than 5 cm. Oral or intravenous administration of metronidazole resulted in resolution of fever, toxemia, and pain in 80% of patients with liver abscess without complications within 48 to 72 hours of treatment. Said patient also experienced clinical improvement during Metronidazole treatment. According to Luthariana L, 2005., wide spectrum antibiotics could be given for initial therapy before results of the patient's culture examination is obtained. Administration of antibiotic is to anticipate amoebiasis considering the fact that 80% of pyogenic liver abscesses are mixed infections between aerobic and anaerobic microorganisms.^{2,16}

Diagnosis of empyema et causa amoebic liver abscess was made based on the complaints of shortness of breath since 1 week prior to admission, relieved by lying facing the right side, and fluctuating fever. Coughing since 2 weeks prior, no phlegm nor blood. The patient's chest x-ray was suggestive of massive right pleural effusion with bronchopneumonia, along with amoebic liver abscess with positive anti-amoeba results. According to Luthariana L., 2005, empyema could be caused by direct spread of abscess or rupture of abscess into the pleural cavity, spontaneously or caused by trauma.

From general physical examination, the obtained data were blood pressure of 100/70mmHg, pulse 96x/minute, respiratory rate 30x/minute, temperature 38.50C, oxygen saturation 98% with NRM 15 liters per minute and anemic conjunctiva. Pulmonary physical examination showed by inspection that the chest wall is asymmetrical and movement of the right chest wall is left behind. Through palpation, right vocal fremitus was decreased compared to the left, and pulmonary percussion was dull on the right hemithorax. Through auscultation, bronchovesicular respiratory sound was inaudible from as high as ICS II, crackles (+). According to Salles JM 2007, patients with liver abscess could then develop into pleuro-pulmonary amoebiasis with clinical manifestations such as shortness of breath, cough, and pleuritic pain.²⁸

From laboratory examinations, results of a positive 92.4 unit anti-amoeba was obtained, no growth on sputum culture, chest X-ray showed homogeneous opacity on the right hemithorax at the level of right posterior ICS II with the impression of a massive right pleural effusion with bronchopneumonia and chest ultrasound showed the results of a right pleural effusion. According to Light RW. 2013 diagnosis of amoebiasis should be considered in all patients with right pleural effusion without other clear explanations. Chest radiography shows small to moderately sized pleural effusions, along with elevation of the hemidiaphragm. In this situation, pleural fluid is not yet well characterized, but seemed to be exudative in nature. Diagnosis is assisted by serological tests. Sensitivity of antibody test towards *E. histolytica* is 95% for patients with extraintestinal amoebiasis. Serological test is limited as a diagnostic tool in

endemic areas because individuals would remain seropositive for years after convalescence of infection and a seropositive level of more than 25% might be found in several areas.²³

The patient's PSI score of 92 was categorized into grade 4, with a predicted mortality rate of 2.9-8.2% with moderate risks, and is required to receive inpatient treatment at the hospital. For treatment of the patient's pneumonia, intravenous 1 gram Ceftriaxone was administered twice a day according to CAP treatment by the American Thoracic Society. In this patient, no macrolide combination was given, as according to Murter F, 2019, there were no differences between Ceftriaxone monotherapy and Ceftriaxone + Azithromycin for empirical therapy of CAP. The patient was then diagnosed with empyema et causa liver abscess. For the patient's treatment, antibiotics such as 750 mg Metronidazole three times a day for 10 days and 1 gram Ceftriaxone twice a day were administered. According to Light RW. 2013, choice of treatment for pulmonary amoebiasis is metronidazole, 500 mg to 750 mg, orally administered three times a day for 10 days.^{20,21,22}

A thoracentesis was performed on the patient to remove fluid from the pleural cavity, a volume of 1.5 liters was obtained with the pleural fluid analysis results of brownish color, 90 PMN cells, 10 MN cells, 16,250/mm³ cell count and negative Rivalta test results. Characteristics of the fluid in the pleural cavity at this stage is exudative, and generally dominated by polymorphonuclear leukocytes (PMN) cells, with normal glucose and pH levels. Pleural fluid LDH level > 2/3 of serum LDH, and no bacterial organisms present. Antimicrobial therapy and adequate drainage are the cornerstones of treatment for this disease.²⁹

The patient was diagnosed with amoebic liver abscess and empyema et causa liver abscess. Liver abscess is formed by parasitic lytic activities. Progression of abscess could then affect the diaphragm and a pleuropulmonary complication could occur directly. When the liver abscess spreads towards the diaphragm, adhesion is formed between the surface of the liver and the diaphragm, extending to between the diaphragm and lung base. A hepatopulmonary fistula could cause amoebic empyema. This hepatopulmonary fistula could be caused by several things such as congenital deformity, liver abscess, secondary

biliary tract obstruction, blunt or sharp trauma, or even iatrogenic causes. Liver abscess is the main predisposition of fistula formation. Symptoms that are most commonly found include fever, productive cough, chest pain, right upper abdominal pain, jaundice, and bile stained sputum. Pleural effusion occurs through two mechanisms associated with amoebic liver abscess. The first is when amoebic abscess cause irritation towards the diaphragm or sympathetic pleural effusion. Diaphragm inflammation caused by adjacent abscess cause elevated capillary permeability in the diaphragm pleura and causes accumulation of pleural fluid. Second, amoebic liver abscess also cause a pleural effusion when the abscess is ruptured through the diaphragm and into the pleural cavity.²³

References

- Torre A, Kershenobich D. Amebic liver abscess. *Annals of hepatology*. 2002;1(1):45-7.
- Loscalzo J, Fauci A, Kasper D, Hauser S, Longo D, Jameson J. eds. *Harrison's Principles of Internal Medicine*, 21e. McGraw Hill; 2022
- Castillo S, Manterola C. Morphological Characteristics of Liver Abscesses According its Etiology. *International Journal of Morphology*. 2020;38(2):406-414. doi: 10.4067/S0717-95022020000200406
- Novia J, Cahyadi A. Gangguan Fungsi Hati pada Pasien Abses Hati Ameba dengan Lama Perawatan di Rumah Sakit Atmajaya. *Journal Of The Indonesian Medical Association*. 2018;68(2):72-5. doi: 10.47830/jinma-vol.68.2-2018-88
- Haque R, Huston CD, Hughes M, Houpt E, Petri Jr WA. Amebiasis. *New England journal of medicine*. 2003; 348(16):1565-73. doi: 10.1056/NEJMra022710
- Wuerz T, Kane JB, Boggild AK, Kraiden S, Keystone JS, Fuksa M, Kain KC, Warren R, Kempston J, Anderson J. A review of amoebic liver abscess for clinicians in a nonendemic setting. *Can J Gastroenterol*. 2012;26(10):729-33. doi: 10.1155/2012/852835.
- Anesi JA, Gluckman S. Amebic liver abscess. *Clin Liver Dis (Hoboken)*. 2015;6(2):41-43. doi: 10.1002/cld.488.
- Dhamrah U, Solomon N, Lal N. Bacterial Superinfection of Amoebic Liver Abscess. *Journal of Investigative Medicine High Impact Case Reports*. 2020;8:2324709620926900. doi: 10.1177/2324709620926900
- Jackson-Akers JY, Prakash V, Oliver TI. Amebic Liver Abscess. StatPearls [Internet]. 2020 Aug 10. <https://www.ncbi.nlm.nih.gov/books/NBK430832/>
- Lokanadham D. Clinical study of liver abscess at a tertiary care hospital. *International Journal of Recent Trends in Science and Technology*. 2015;15(3):654-56.
- Kumar S. Amoebic Liver Abscess: A Complete Overview in Tertiary Care Centre. *National Journal of Laboratory Medicine*. 2017;6(4). doi:10.7860/NJLM/2017/30483:2263.
- Marianna GM, Marco M, George YW. The Evolving Nature of Hepatic Abscess: A Review. *Journal of Clinical and Translational Hepatology*. 2016; 4: 158-168. doi: 10.14218/JCTH.2016.00004
- Dutta A, Kishangunj. 2012. Management of Liver Abscess. *Medicine Update* 2012. Vol.22
- Nusi IA. 2015. Abses Hati Amuba. In Setiati dkk (ed). *Buku Ajar Ilmu Penyakit Dalam Jilid II Edisi VI*. Jakarta: FKUI, pp: 1991-4.
- Khim G. 2019. Liver abscess: diagnostic and management issues found in the low resource setting. *British Medical Bulletin*, 2019; 132:45-52. doi: 10.1093/bmb/ldz032.
- Sharma S, Ahuja V. Liver Abscess: Complications and Treatment. *Clinical Liver Disease*, 2021; 18(3):122-126. doi: 10.1002/cld.1128
- Sahn SA. Diagnosis and management of parapneumonic effusions and empyema. *Clin Infect Dis*. 2007;45(11):1480-6. doi: 10.1086/522996.
- Shebl E, Paul M. Parapneumonic Pleural Effusions And Empyema Thoracis. [Updated 2022 Aug 8]. In: StatPearls [Internet]. Treasure Island (FL): StatPearls Publishing; 2022 Jan-.
- Helexandra Y. Parapneumonic Effusion (Ppe) Dengan Congestive Heart Failure (Chf) Pada Pasien Yang Di Rawat Di Bagian Jantung. *Jurnal Human Care*. 2022;7(1). doi: 10.32883/hcj.v7i1.1567.
- Metlay JP. 2019. Diagnosis and Treatment of Adults with Community-acquired Pneumonia. *Am J Respir Crit Care Med*. 2022;200(7):45-67. doi: 10.1164/rccm.201908-1581ST
- Lee MS. 2018. Guideline for Antibiotic Use in Adults with Community-acquired Pneumonia. *Infect Chemother* 2018;50(2):160-198. doi: 10.3947/ic.2018.50.2.160
- Murter F. 2019. Ceftriaxone Monotherapy vs. Ceftriaxone Plus Azithromycin for the Treatment of Community-Acquired Pneumonia in Hospitalized, Non-ICU Patients. *Open Forum Infect Dis*. 2019 Oct; 6(Suppl 2): S748-S749. doi: 10.1093/ofid/ofz360.1877
- Light RW, Pleural Effusion Due to Parasitic Infection, *Pleural Diseases*, Ed 6th; 2013: p.271-3.
- Lyche KD, Jensen WA, Kirsch CM, et al. Pleuropulmonary manifestation of hepatic amebiasis. *West J Med*. 1990; 153:275-278.
- Sharma OP. 1993. Lung diseases in the tropics. Part 2: Common tropical lung diseases: diagnosis and management. *Tubercle and Lung Disease*. 1993;74(6): 359-370. doi: 10.1016/0962-8479(93)90078-C.
- Kristin DP. 2020. Pulmonary Amebiasis Complicated With Massive Left Empyema And Respiratory Failure: A Case Report. *Sanamed*. 2020;15(1): 45-49.
- Makkar RPS, Sachdev GKR. 2003. Alcohol Consumption, Hepatic Iron Load and the Risk of Amoebic Liver Abscess: A Case-control Study. *Intern Med*. 2003;42(8):644-9. doi: 10.2169/internalmedicine.42.644.
- Salles JM, Moraes LA, Silvia MC. Invasive amebiasis: an update on diagnosis and management. *Expert Rev Anti Infect Ther*. 2007;5(5):893-901. doi: 10.1586/14787210.5.5.893.
- AlGhamdi ZM, oumarah DN, Alshammary S, Elbawab H, Pleural Empyema as a Complication of Pyogenic Liver Abscess: Can the Minimum Achieve the Optimal? A comparison of 3 Approaches. *American*

- Journal of Case Reports*. 2021; 22: e935169-1-e935169-9. doi: 10.12659/AJCR.935169.
30. Luthariana L, Lesmana LA, Rubangi S, Nasir UZ, Iswari RT. Management of Pyogenic Liver Abscess and Empyema as Its Complication. *The Indonesian Journal of Gastroenterology, Hepatology, and Digestive Endoscopy*. 2005: 22-26. doi: 10.24871/61200522-26.